

Necrotic Encephalitis associated with a Toxoplasma-like Protozoan Infection in Lambs

Monier. A. M. Sharif¹, Adel. B. M. Mohamed^{1*}, Wafa. M Ibrahim¹, Ibrahim. M. Eldaghayes², Abdulwahab. M. Kammon², Abdunaser. S. Dayhum²

1. Department of Basic Veterinary Science, Faculty of Veterinary Medicine, University of Omar Al-Mukhtar, Albeida-Libya.
2. Faculty of Veterinary Medicine, University of Tripoli – Libya.

* Corresponding author Adel. B. M. Mohamed

ABSTRACT

Introduction: A total of 32 young (1-3 months-old) lambs suffered from mortal neurological signs in a period of three months. The lambs were among the offspring of a herd of 300 sheep, in Tarhouna city, Libya. The affected lambs were initially treated with antibiotics, multivitamins and mineral supplements, however, none of these treatments attenuated the death toll among the small lambs.

Methods: Three lamb carcasses were submitted to the National Center for Animal Health (NCAH) for post mortem examination. Gross pathological examination of the brains detected hydatid cysts and yellowish lesions within the cerebral cortex.

Results: The histopathologic examination of the brain showed the presence of inflammatory lesions and necrotic features surrounded by granulomatous inflammatory patterns, which are accompanied by a few parasitic cysts. Ordinary and modified Ziehl-Neelsen stains for bacterial infection were performed, but the results did not strongly indicate bacterial infection. Toxoplasmosis, particularly *T. gondii*, and Neospora were first suspected. Immunohistochemistry testing for *T. gondii* did not show any conclusive indication for the presence of this pathogen. However, meticulous microscopic examination (100x) of the histopathologic features and the patterns of host-pathogen interaction of toxoplasmosis indicate that these lambs may have suffered from necrotic encephalitis associated with a different type of toxoplasmosis.

Key words : Toxoplasma, Neospora, Necrotic encephalitis, Ovine, Libya.

INTRODUCTION

Sheep commonly suffer from protozoan parasitic infections, particularly toxoplasmosis, which can pass the placental barrier and cause (based on the time of the pregnancy) embryonic death, abortion, still birth, and death for newly born lambs^{1,2,3}.

Toxoplasmosis is a disease of most warm-blooded animals, including humans, caused by an obligatory intracellular protozoan parasite⁴.

Ovine Toxoplasmosis was first reported in New Zealand by Hartley⁵. Since it was first discovered, toxoplasmosis has become a pandemic zoonotic infection³. In livestock, toxoplasmosis mainly targets the reproductive organs in both genders. The pathogens can transmit from mother to fetus and induce abortion, death or weak offspring. This eventually causes considerable losses in sheep during pregnancy, impacting livestock industries especially in low-income countries^(1,6,7,8).

The initial infection occurs by ingestion of sporulated oocysts that are shed with cat feces. Affected by the acidic environment of the sheep gut, each sporulated oocyst releases sporozoites that penetrate the intestinal wall and migrate via the lymphatic and the portal systems. This allows them to disseminate to body organs and tissues, including the reproductive system, central nervous system and muscle tissues, where sporozoites differentiate to tachyzoites; the infective stage. Tachyzoites penetrate the cell membrane and become enclosed in a parasitophorous vacuole, which is considered a unique characteristic of toxoplasmosis infection. The tachyzoites go through asexual multiplications. Once they reach 16 tachyzoites, the cell ruptures to release tachyzoites that infect other cells. ^(9,10). In the present paper, we investigate the potential cause of an outbreak of death in newborn lambs suspected to be caused by toxoplasmosis in Tarhouna city.

CASE DETAILS AND RESEARCH METHODOLOGY

A herd of newborn lambs suffered from semi-neurologic signs. Most of the ill cases died in the first three months of age. The case history and the initial diagnosis showed that the lambs suffered from loss of appetite and low water in addition to variable neurologic disorders. The lambs were subjected to treatment with antibiotics but that did not help in reducing the death rate among the young lambs. Three carcasses of ill lambs were subjected to post-mortem investigations at the National Center for Animal Health. Tissue samples from the liver, the brain and digestive system were taken from each lamb carcasses for histopathologic examination. The samples were fixed in neutral buffered 10% formalin solution. Each specimen from the tissue was processed, embedded in paraffin, sectioned at 4 μ m thickness and stained with Hematoxylin and Eosin (H&E). Samples were examined under 100x magnification power of Leica light microscope at the faculty of veterinary Medicine, at Omar Al-Mukhtar University.

RESULTS:

The postmortem and gross examinations showed no significant gross pathologic lesions in the body organs except within the brain, where signs of sporadic congestion, greyish and yellow granulomatous lesions (Fig. 1) and hydatid cysts were detected (Fig. 2).

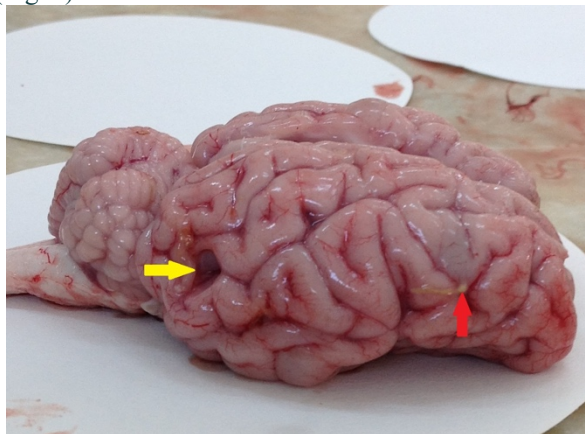


Fig.1. Gyrus edema, greyish discoloration and superficial yellowish granuloma (red arrow). A cavity with an irregular wall is due to a ruptured cyst can be seen at the right caudal part of the temporal lobe (yellow arrow)

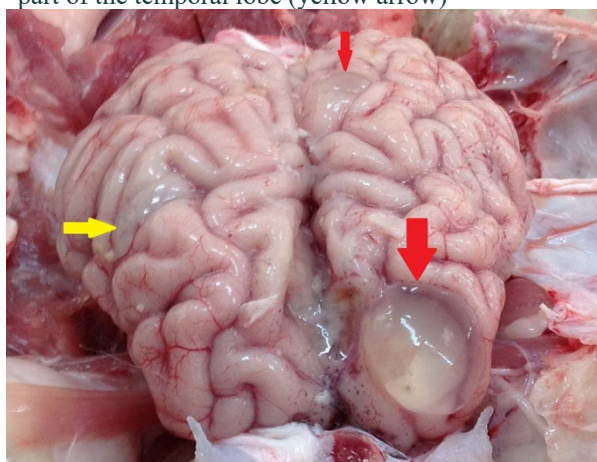
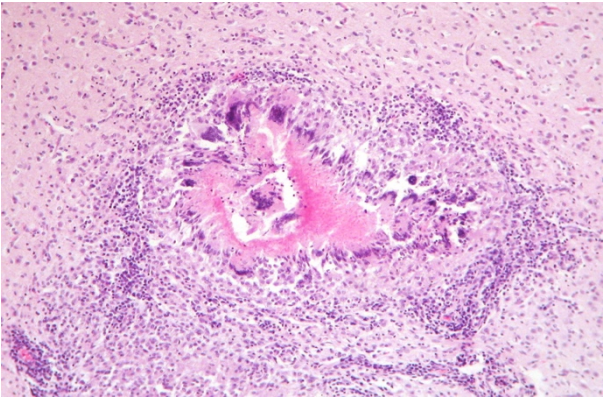


Fig.2. Multiple cenuri are embedded in the brain tissue. Large cyst occupies the anterior part of the left frontal lobe (Large red arrow) with hyperemia and edema in the adjacent meninges. Small cyst is embedded in a gyrus in the medial side of the parietal lobe (small red arrow). Gyrus edema and greyish discoloration (yellow arrow)

Histopathologic examination of the brain showed a figure of necrotic lesion surrounded by a collar of granulomatous inflammatory cells (Fig.3).



. Fig.3. Sever necrosis is surrounded by granulomatous inflammation, brain. H&E Stain (X 4)

Higher magnification of the granulomatous lesion showed aggregation of lymphocytes, monocytes and eosinophils, as well as perivascular infiltration within the brain tissue (Figs. 4&5).

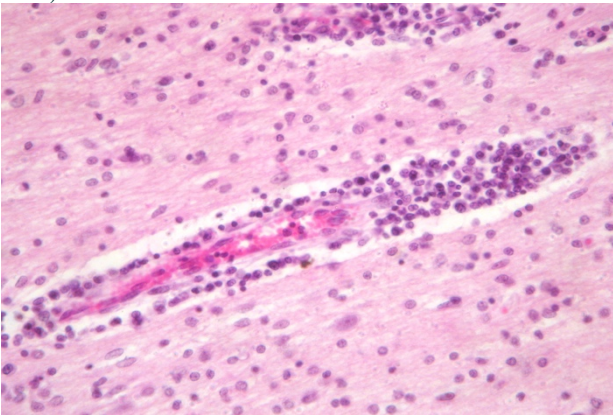


Fig.4. Moderate lymphocytic perivascular infiltration in brain tissue. H&E (X10).

A deeper investigation of the inflammatory region showed a vegetative protozoan cyst (Fig. 6).

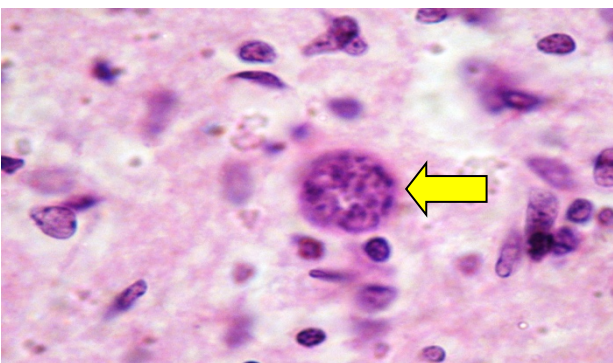


Fig.6: Protozoan tissue cyst in the brain tissue (Yellow arrow). H&E (X100)

DISCUSSION

The initial investigations and the clinical findings were consistent with a neurological injury, which was confirmed by the postmortem and histopathologic investigation of the brain tissue which showed clear features of inflammation in the brain tissue. Such inflammatory reactions are commonly correlated with bacterial infection. However, the histopathologic staining with both ordinary and modified Ziehl-Neelsen failed to show any indication of the bacterial infection. In a deeper and comprehensive histopathological search around the necrotic area, a cyst of tachyzoite-like structures was observed under higher-power magnification (x1000). The presence of sporulated oocysts surrounded by inflammatory cells and necrotic lesions provided an indication of the host-parasite interaction underlying the outbreak. The formation of toxoplasma cysts in the tissues is a characteristic step that initiates host-pathogen inflammatory interaction¹¹. In most toxoplasmosis infections, histologic brain sections obtained from dead lambs generally exhibit cysts accompanied by typical inflammatory features¹².

Due its ubiquity and prevalence, *T. gondii* was initially considered the most likely potential cause of infection. However, immunohistochemistry testing failed to detect any reaction with *T. gondii* antibodies. This might indicate that the infections are caused by another species of *Toxoplasma* that is not strongly recognized by this antibody.

The hydatid cyst, which is a fluid-filled cyst that can develop in different body organs, is among the distinctive features of infections with parasites such as the tapeworm *Echinococcus granulosus*. In the newly born lambs reported in this study, echinococcosis is considered less likely due to the absence of hydatid cysts in the rest of body organs. In addition, tapeworm eggs do not cross the placental barrier to infect the fetus. Finally, the histopathologic investigations of the examined area of the brain show necrosis and inflammation, which is less likely to be present in cases of tapeworm infection.

Neospora caninum is an interesting candidate that has similarities in structure, pathogenic reactions and pathologic lesions to *Toxoplasma*¹³. In addition, both parasites share the same range of hosts, with some differences in the order of the intermediate and the definitive host; sheep and other small ruminants are the definitive hosts of toxoplasmosis, whereas dogs are the definitive hosts of *Neospora caninum*¹⁴.

One complicating factor in this study is the challenge of making a definitive diagnosis of toxoplasmosis, since most mothers do not show clinical signs, which are generally restricted to the fetuses only¹.

The findings of this study do not clearly show a definite cause of the infection among the affected lambs. However, the ubiquity of toxoplasmosis in Libya, its established ability to cross the placenta and infect fetuses, and the findings of the histopathologic investigations make toxoplasmosis the main suspected cause of this sporadic infection in this herd.

Further serological and molecular investigations should be conducted to detect the antibody reactivity and the genetic

character of the infectious agent. The study recommends paying more attention to the endemic and the pandemic diseases in Libya, principally the parasitic infections and conducting campaigns for clinical investigations, vaccinations and treatment.

REFERENCES

1. Dubey, J.P. and Beattie, C.P., 1988. Toxoplasmosis of animals and man. CRC Press, Inc.
2. Dubey, J.P., Welcome, F.L., 1988. Toxoplasma gondii induced abortion in sheep. J. Am. Vet. Med. Assoc. 193, 697–700.
3. Dubey, J.P., 2010. Toxoplasmosis of Animals and Humans, 2nd ed. CRC Press, Boca Raton, FL, pp. 1–313.
4. Innes, E.A., Bartley, P.M., Buxton, D., Katzer, F., 2009. Ovine toxoplasmosis. Parasitology 136, 1887–1894.
5. Hartley, W.J., Jebson, J.L., McFarlane, D., 1954. New Zealand type II abortion in ewes. Aust. Vet. J. 30, 216–218.
6. Buxton, D., Maley, S.W., Wright, S.E., Rodger, S., Bartley, P., Innes, E.A., 2007. Toxoplasma gondii and ovine toxoplasmosis: new aspects of an old story. Vet. Parasitol. 149, 25–28
7. Anastasia, D., Elias, P., Nikolaos, P., Charilaos, K. and Nektarios, G., 2013. Toxoplasma gondii and Neospora caninum seroprevalence in dairy sheep and goats mixed stock farming. Veterinary parasitology, 198(3-4), pp.387-390.
8. Masala, G., Porcu, R., Madau, L., Tanda, A., Ibba, B., Satta, G. and Tola, S., 2003. Survey of ovine and caprine toxoplasmosis by IFAT and PCR assays in Sardinia, Italy. Veterinary parasitology, 117(1-2), pp.15-21.
9. Taylor, S., Barragan, A., Su, C., Fux, B., Fentress, S.J., Tang, K., Beatty, W.L., El Hajj, H., Jerome, M., Behnke, M.S. and White, M., 2006. A secreted serine-threonine kinase determines virulence in the eukaryotic pathogen Toxoplasma gondii. Science, 314(5806), pp.1776-1780.
10. Elmore, S.A., Jones, J.L., Conrad, P.A., Patton, S., Lindsay, D.S., Dubey, J., 2010. Toxoplasma gondii: epidemiology, feline clinical aspects, and prevention. Trends Parasitol. 26, 190–196.
11. Benavides, J., Maley, S., Pang, Y., Palarea, J., Eaton, S., Katzer, F., Innes, E.A., Buxton, D. and Chianini, F., 2011. Development of lesions and tissue distribution of parasite in lambs orally infected with sporulated oocysts of Toxoplasma gondii. Veterinary parasitology, 179(1-3), pp.209-215.
12. Edwards, J.F. and Dubey, J.P., 2013. Toxoplasma gondii abortion storm in sheep on a Texas farm and isolation of mouse virulent atypical genotype T. gondii from an aborted lamb from a chronically infected ewe. Veterinary Parasitology, 192(1-3), pp.129-136.
13. Buxton, D. (1998). Protozoan infections (toxoplasma gondii, neospora caninum and sarcocystis spp.) in sheep and goats: Recent advances. Veterinary research, 29(3-4): 289.
14. Sánchez-Sánchez R, Vázquez P, Ferre I, Ortega-Mora LM. Treatment of Toxoplasmosis and Neosporosis in Farm Ruminants: State of Knowledge and Future Trends. Curr Top Med Chem. 2018;18(15):1304-1323. doi: 10.2174/1568026618666181002113617. PMID: 30277158; PMCID: PMC6340160.